

Dr. Douglas G Watt
Euston Place Dental Practice

Onlays and crown for lower right quadrant using model free digital workflow

Solutions featured:

3Shape TRIOS intraoral scanner
3Shape Dental System



Case Information

The patient attended for an emergency dental appointment after fracturing the mesio-lingual cusp of her lower right first molar tooth. Following an initial 3Shape TRIOS intraoral scan and discussion with the patient, it was decided that restoration of the entire quadrant was indicated. This was due to the heavily restored teeth in this area and the risk of further fracture in the future. The sharp edge on the amalgam restoration adjacent to the fracture was smoothed at this time.

All teeth responded positively to vitality test barring the lower right first premolar which had undergone previous root canal therapy. There was no sign of apical pathology on radiographic examination.

3shape 

Treatment plan

The treatment plan was to carry out restorations on all teeth with cuspal coverage whilst maintaining as much enamel to bond to as possible and maintaining tooth tissue. The decision was made to remove all the amalgam restorations and place composite cores where necessary. The lower right first and second molars and lower right second premolar were prepared for lithium disilicate onlays and the lower right first premolar for a full coverage lithium disilicate crown.

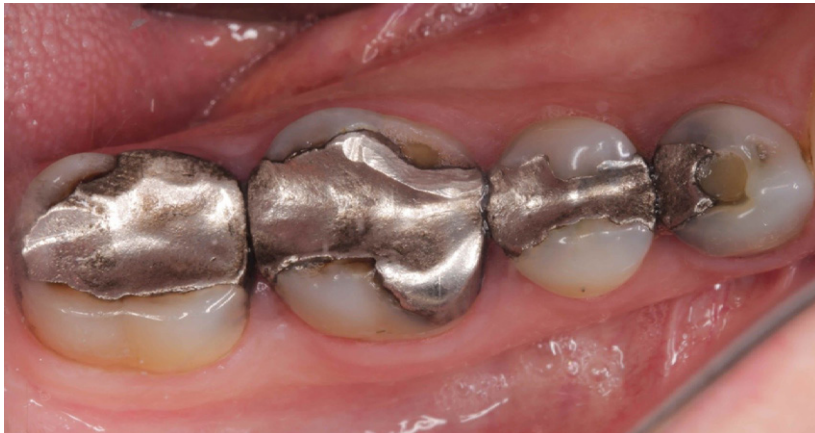

Fig. 1 (i)

Patient situation before (Fig. 1i, ii)

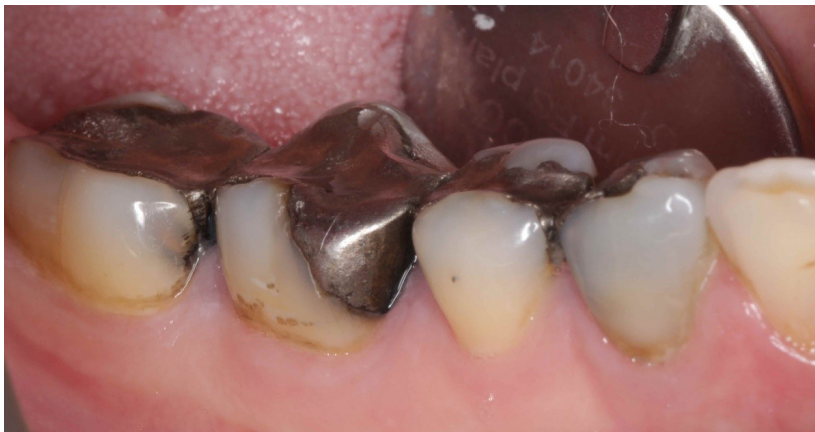

Fig. 1 (ii)

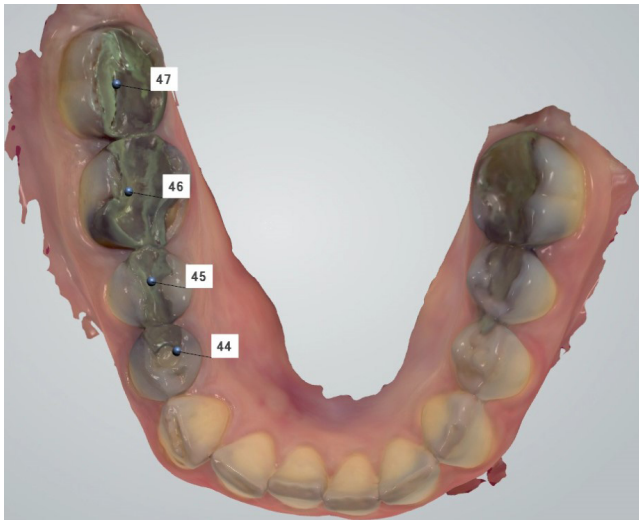


Fig. 2

All intraoral scanning was carried out using a 3Shape TRIOS 3 intraoral scanner. Pre-preparation scan. (Fig. 2)

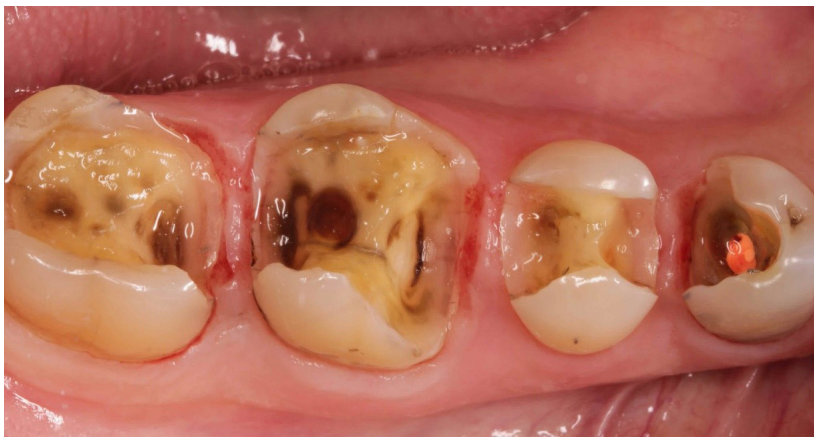

Fig. 3

After removal of the old restorations. (Fig. 3)

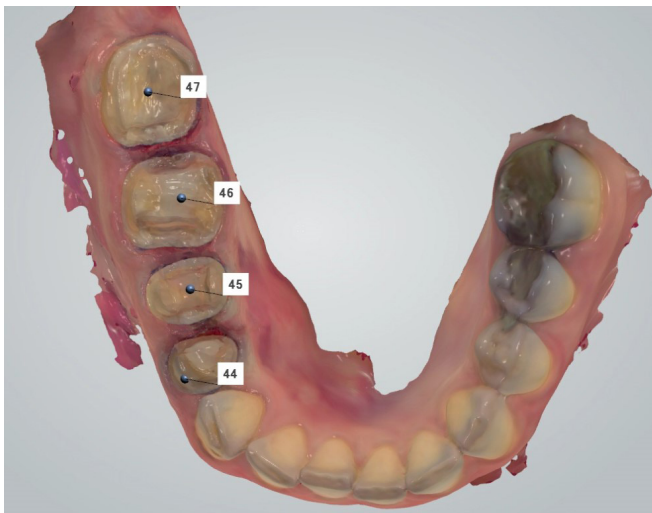
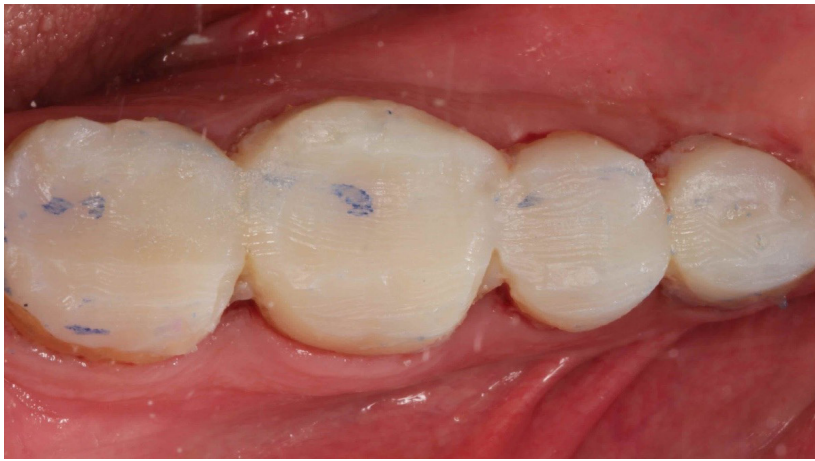

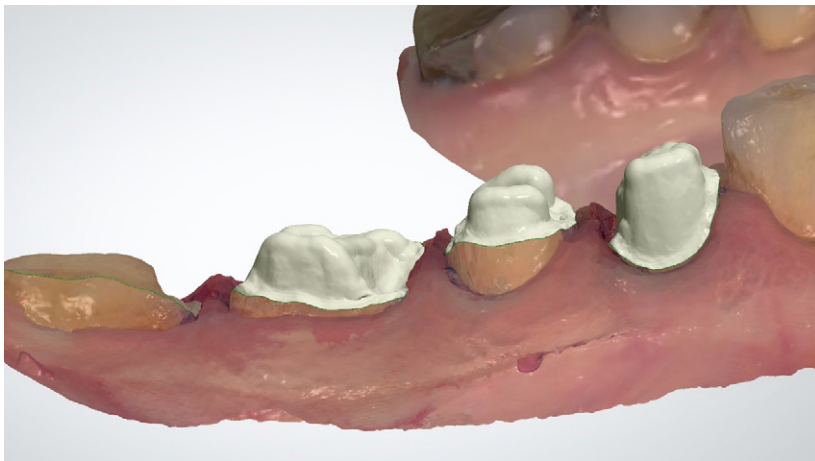
Fig. 4

Preparations stitched into the existing scan. (Fig. 4)



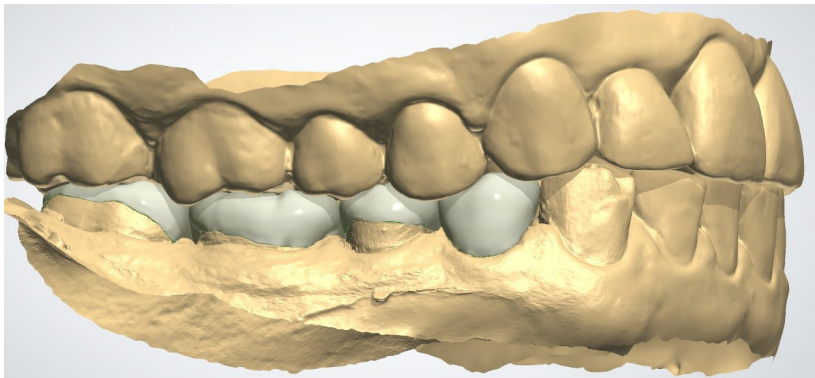
Chairside Provisionals made from pre-reparation matrix of teeth. (Fig. 5)

Fig. 5



The patient was rebooked for the fit appointment two weeks later. The laboratory stages were carried out using 3Shape Dental System. Virtual Die stage (Fig. 6)

Fig. 6



Initial onlay design and attachment to margins. (Fig. 7i, ii)

Fig. 7 (i)

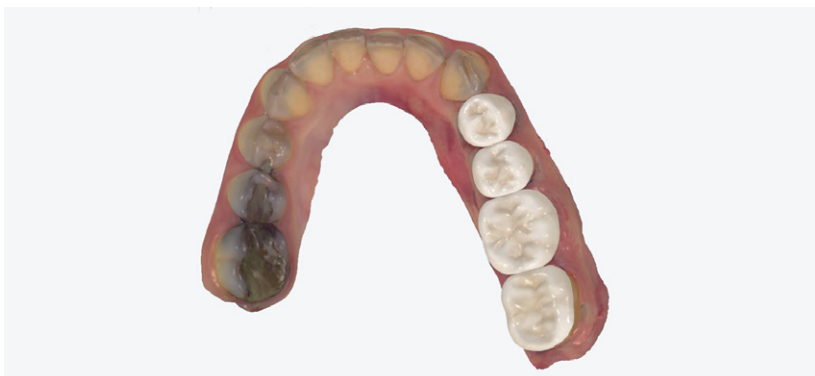

Fig. 7 (ii)

Onlays and crown for lower right quadrant using model free digital workflow

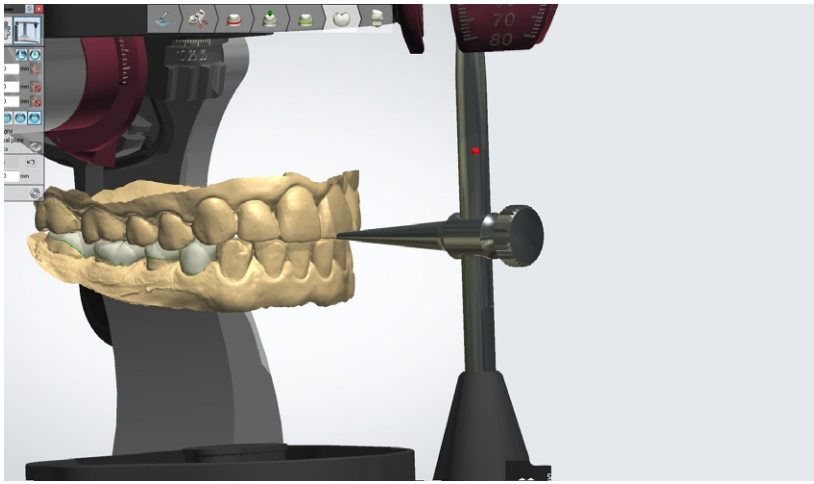


Fig. 8 (i)

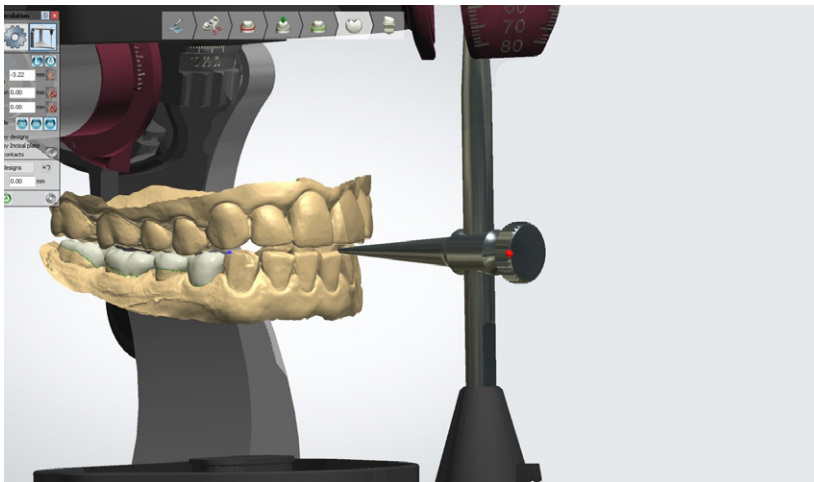


Fig. 8 (ii)

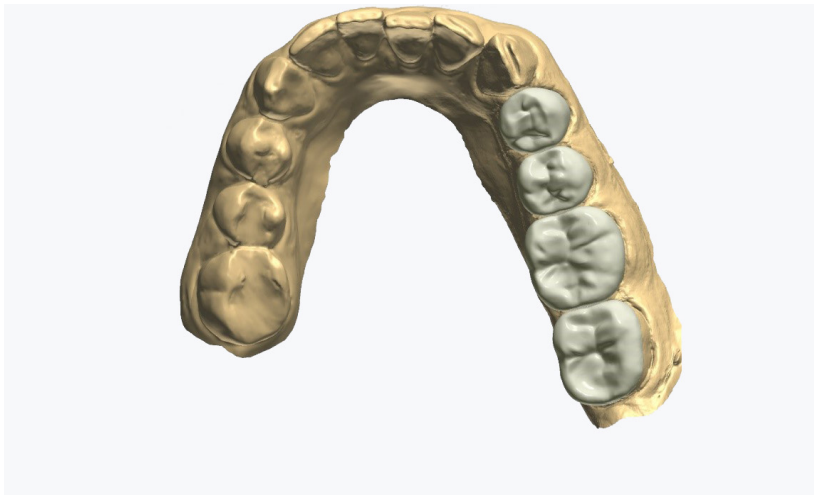


Fig. 9

Virtual Articulator used to remove lateral excursive interferences. (Fig. 8i, ii)

Designs following adaptation by running the virtual articulator. (Fig. 9)

Following try in of the restorations the teeth were isolated under rubber dam. The restorations were hydrofluoric acid etched on the fit surface with 9% hydrofluoric acid gel for 15 seconds and then cleaned in an ultrasonic bath with 90% isopropyl alcohol and 10% water. The fit surface was then treated with a two bottle silane system and left to dry.

The teeth were sandblasted with 29 micron Aluminium oxide to clean the surface and reactivate the bonding layer on the sealed dentine surface, they were then etched with 37% phosphoric acid etchant gel.

The tooth surface was then treated with a bonding agent which was air thinned and left uncured and a dual cure cement with bond activator was applied to the fit surface of the restorations and they were seated. (Fig. 10)

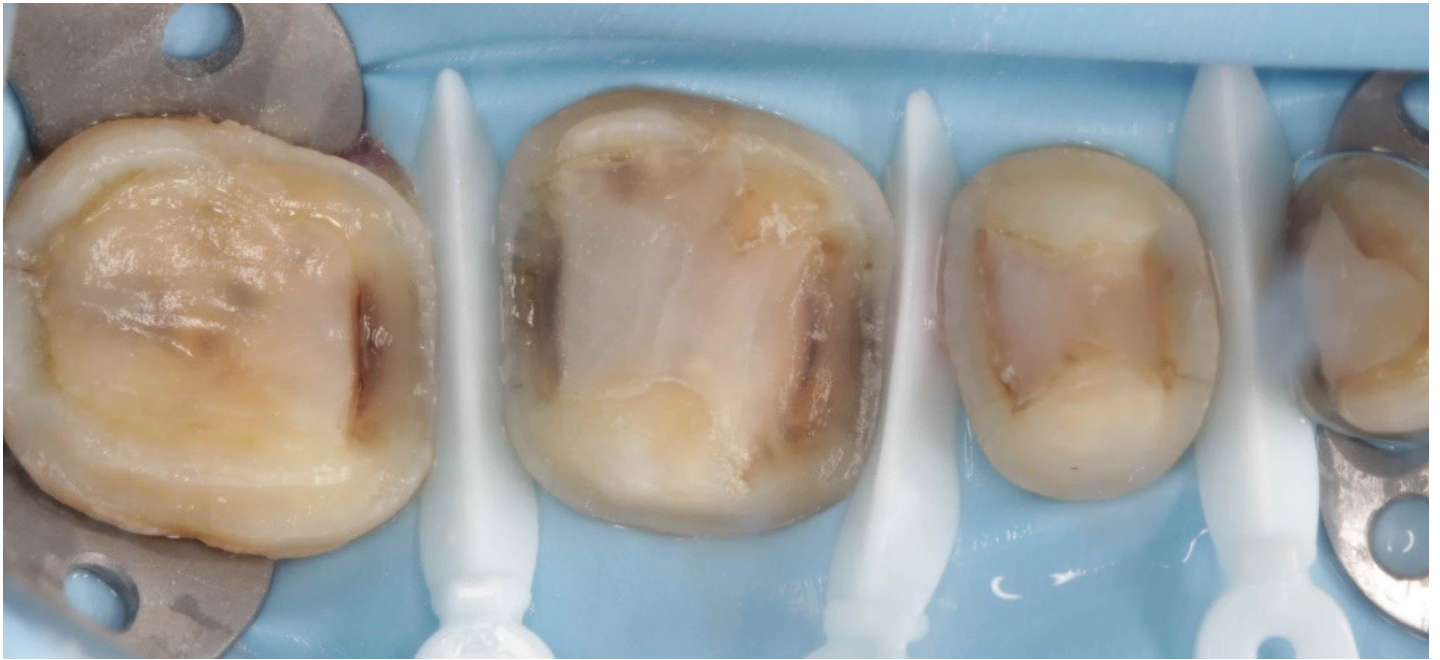


Fig. 10

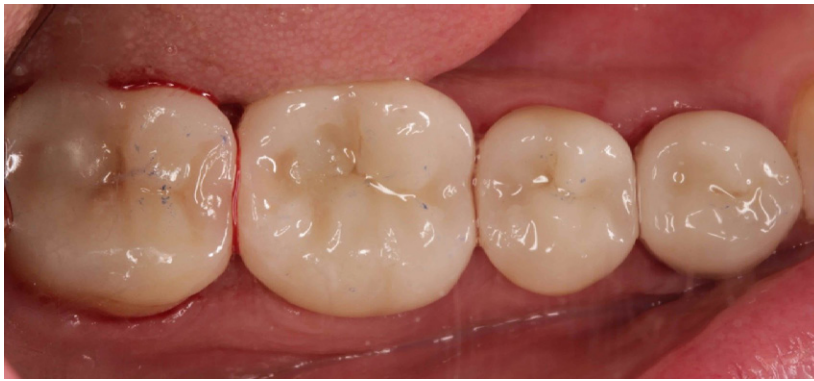

Fig. 11 (i)

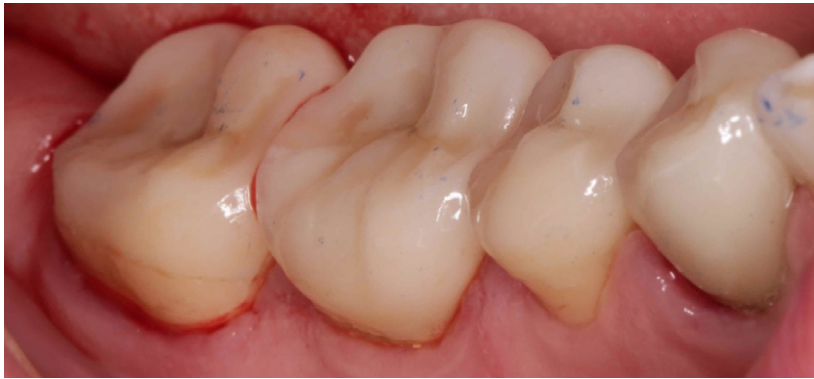

Fig. 11 (ii)

Conclusions

3Shape products facilitated a seamless workflow between surgery and laboratory with increased patient comfort and accuracy. Although at first I was unsure how well this would work as a model free case, the contacts were good and there was minimal occlusal adjustment required at fit. I have always previously found last standing units have caused occlusal issues at fit stage even when there is no a intital deflective contact but very little occlusal adjustment was required here.

This made the treatment go very smoothly and efficiently alongside the initial scan facilitating much better patient communication and allowing the patient to visualise in full colour and three dimensionally why the treatment was being suggested.

The biggest challenge I found during this case, was scanning adjacent subgingival margins and getting a clear marginal definition all the way round the preparation. I found that by placing the retraction cord one tooth at a time, and then scanning it, then removing the retraction cord from that tooth and placing it in the next tooth, I was able to avoid the cord displacing the papilla over the margin of the tooth in front. Fig. 4 – shows the individual tooth prep scans stiched together into one scan.

The major benefit of using a scanner in this situation is that if there is an area lacking definition, you can simply delete and rescan this area. With a conventional impression, it would have meant replacing some cord and retaking the impression, possibly multiple times.

The cement was flash cured for around 5 seconds and excess cement was cleaned off and the contacts flossed. (Fig. 11i, ii)

About Dr. Douglas Watt

Douglas Watt graduated from Birmingham University in 2003. He is a partner in a private practice in Royal Leamington Spa. His interest in dentistry are restorative dentistry, implant dentistry, endodontics and digital dentistry. He is a board member of the International Digital Dental Academy, Full member of the British Academy of Cosmetic Dentistry and a Member of the Faculty of General dental practitioners. He lectures on digital dentistry and mentors other dentists in applications of digital technology.

About 3Shape

3Shape is changing dentistry together with dental professionals across the world by developing innovations that provide superior dental care for patients. Our portfolio of 3D scanners and CAD/CAM software solutions includes the multiple award-winning 3Shape TRIOS intraoral scanner, the upcoming 3Shape X1 CBCT scanner, as well as market-leading scanning and design software solutions for both dental practices and labs.

Two graduate students founded 3Shape in Denmark's capital in the year 2000. Today, 3Shape employees serve customers in over 100 countries from an ever-growing number of 3Shape offices around the world. 3Shape's products and innovations continue to challenge traditional methods, enabling dental professionals to treat more patients more effectively.

Let's change dentistry together

www.3shape.com

3shape 